

Radiology Techniques

The most difficult aspect of Dental radiology for most practitioners is the production of radiographs that are dimensionally correct in size and shape.

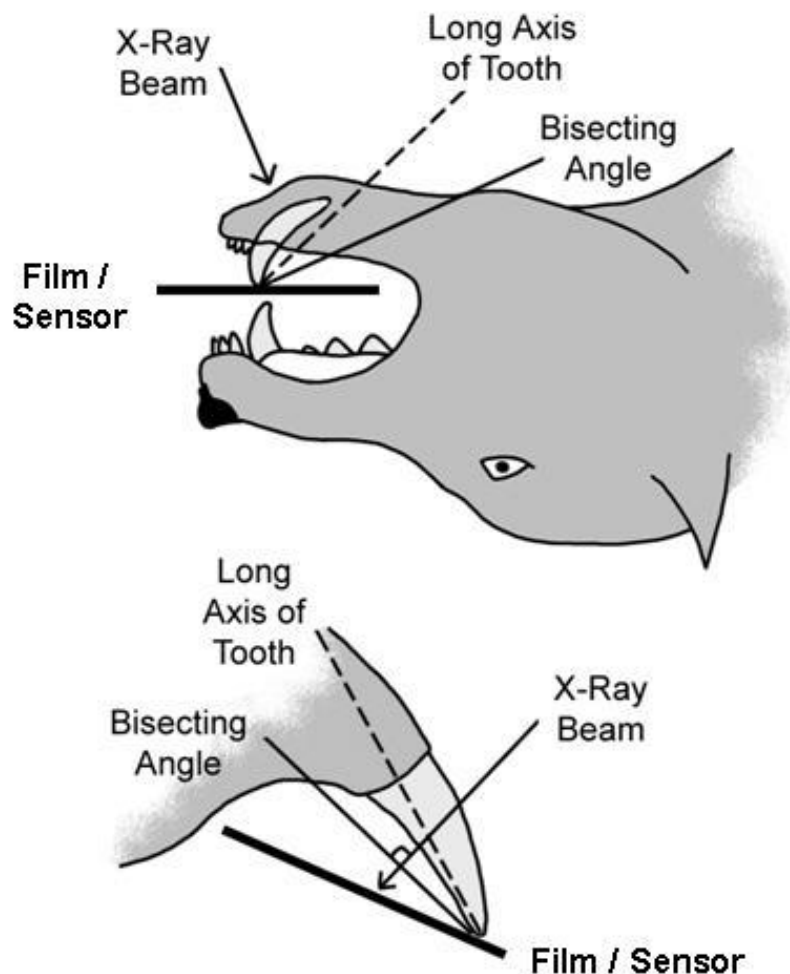
It can be difficult to produce images with no foreshortening or elongation. Traditional radiology of body parts makes use of the standard Parallel technique, where the object being radiographed is parallel to the film/sensor with the x-ray beam being perpendicular to both. The parallel technique is in fact a specific variation of the predominant technique used in Veterinary Dental Radiology – the bisecting angle technique. **iM3 Bisecting angle Guide part No. X8000**

The Parallel Technique.

The parallel technique is used when the film/sensor can be placed parallel to the teeth being radiographed. This is often the case when radiographing teeth and structures of the mandible. The film/sensor often will slip in easily beside the tongue adjacent to the mandible,

The Bisecting angle technique.

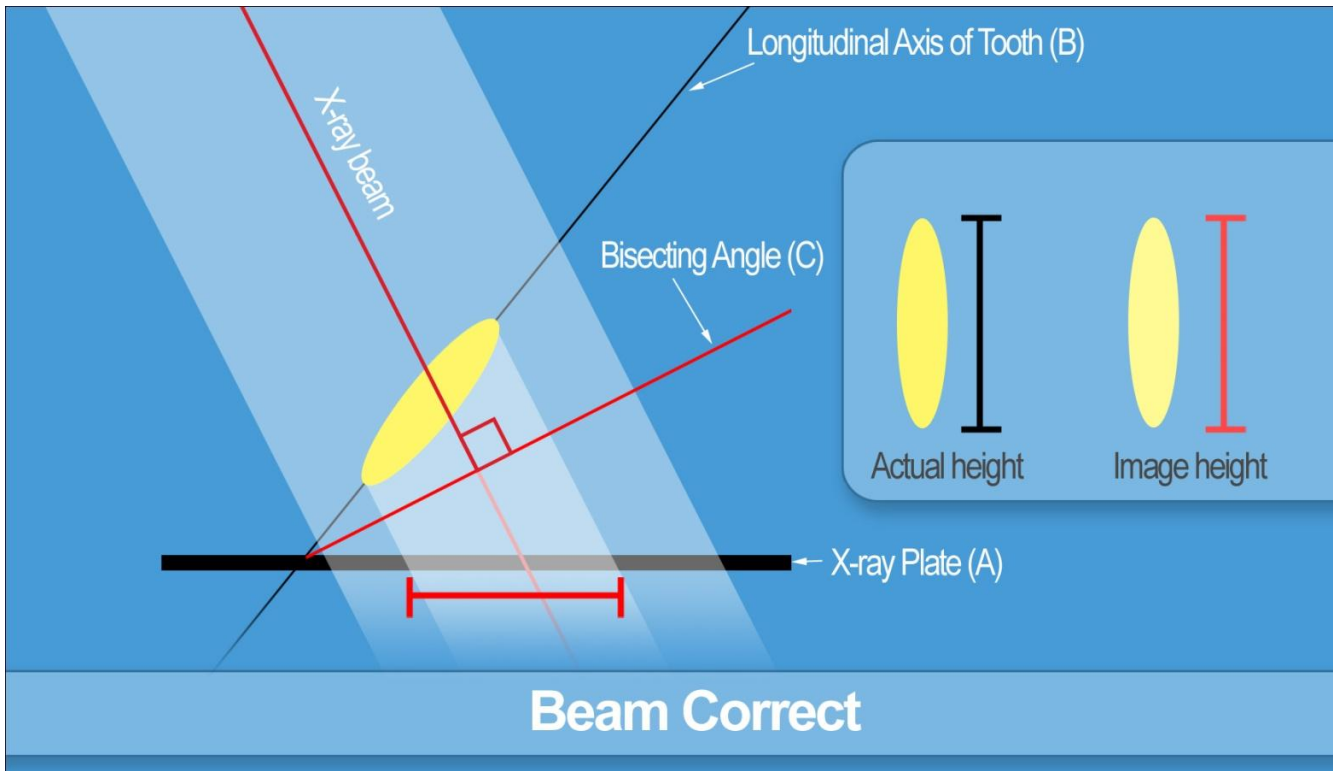
The Bisecting angle technique seems difficult when first approached but can be broken down into a very simple set of steps. The bisecting angle technique is where the primary x-ray beam is directed perpendicular to an imaginary bisecting line. The bisecting line is that line which bisects the angle created between the film/sensor and the long axis of the tooth being radiographed. To accomplish this technique, the film/sensor is placed adjacent to the tooth as close as possible to parallel as the structures of the mouth allow.



Steps for Bisecting Angle Technique:

1. Place film / sensor as parallel as possible to the object being radiographed.
2. the film / sensor makes side A
3. the longitudinal axis of the object is side B
4. Find the angle of AB
5. bisect (halve) the angle of AB creating C
6. direct the primary beam of the X-ray beam perpendicular to C

By using this technique, the image produced will be dimensionally correct, with no elongation or foreshortening.



This is an important technique to use and understand, as a lot of the decisions made and treatments used in dentistry rely on dimensionally accurate images. The bisecting angle technique is the only way to achieve this with the majority of dental radiographs. Even the parallel technique is really a special subset of the bisecting angle technique.



Visit the iM3 website for our full range of Veterinary Digital Dental X-Ray's.
www.im3vet.com